



Imperial College Healthcare

NHS Trust

Miss Rajni Jain FRCOphth

Consultant Ophthalmologist

- Western Eye Hospital
London
- rajnijain@mac.com



Western Eye Hospital A&E

- Open 24 hrs
- Advice line 020-331-23247 (Dr's room)
-
- Onward referral possible if GP letter accompanies patient

RED EYE

- **2-5% GP consultations ophthalmic in nature**
- **Red eye most common Ophthalmic presentation**
- **70% of primary care red eye consist of:**
 - **Bacterial, viral and allergic conjunctivitis**
 - **Episcleritis**
 - **Subconjunctival haemorrhage**

NICE 'Red Eye' Clinical Knowledge Summary

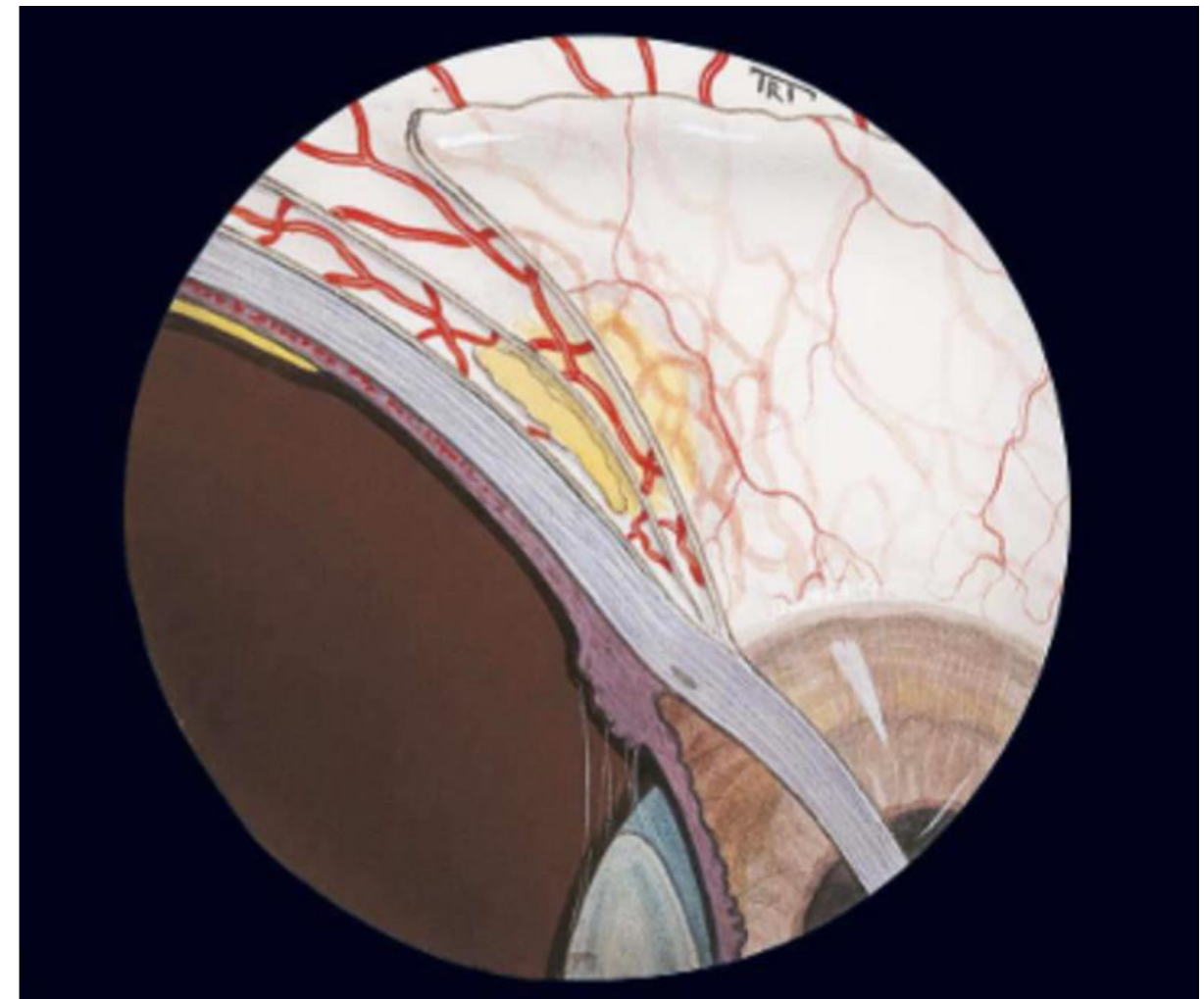
- Always document the history and findings including negative findings of:
 - Visual acuity
 - Pain
 - Photophobia
 - Unilateral or bilateral
- If any red flag is present then a same day specialist referral should be made

Red Eye

- Important to differentiate between
 - LOCALISED redness (patterns will lead to Dx)
 - GENERALISED redness (history will Dx)
- Ensure no corneal opacity - if so REFER urgently (keratitis)

Localised Red Eye

- Sub-conjunctival haemorrhage
- Episcleritis
- Pterygium
- Pingueculum
- Marginal keratitis
- Iritis
- Scleritis



Generalised Red Eye

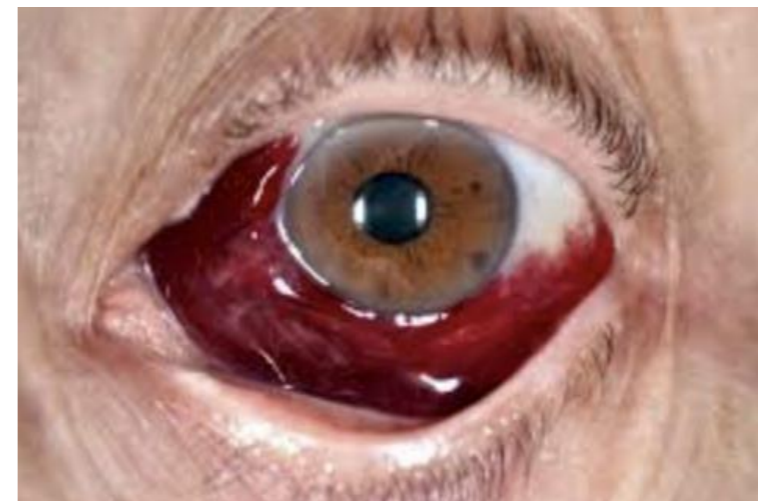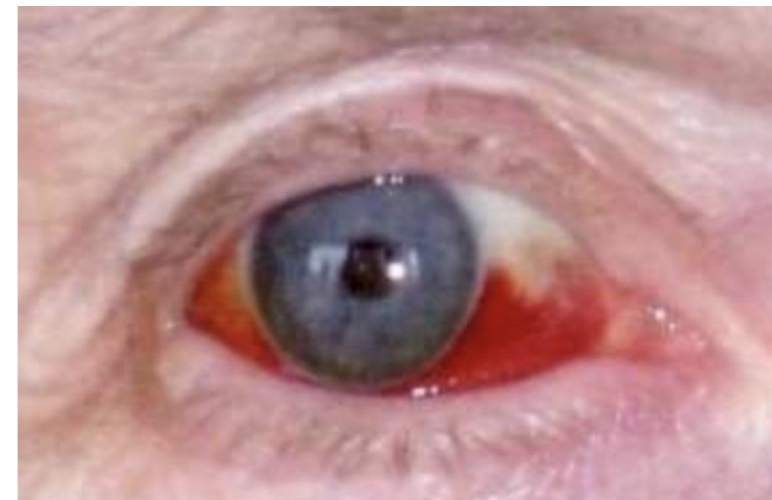- Bacterial conjunctivitis
- Viral conjunctivitis
- Allergic conjunctivitis
- Foreign body
- Acute anterior uveitis
- Acute Glaucoma

Sub-conj haemorrhage

- Looks like spilt blood!
- No view of sclera

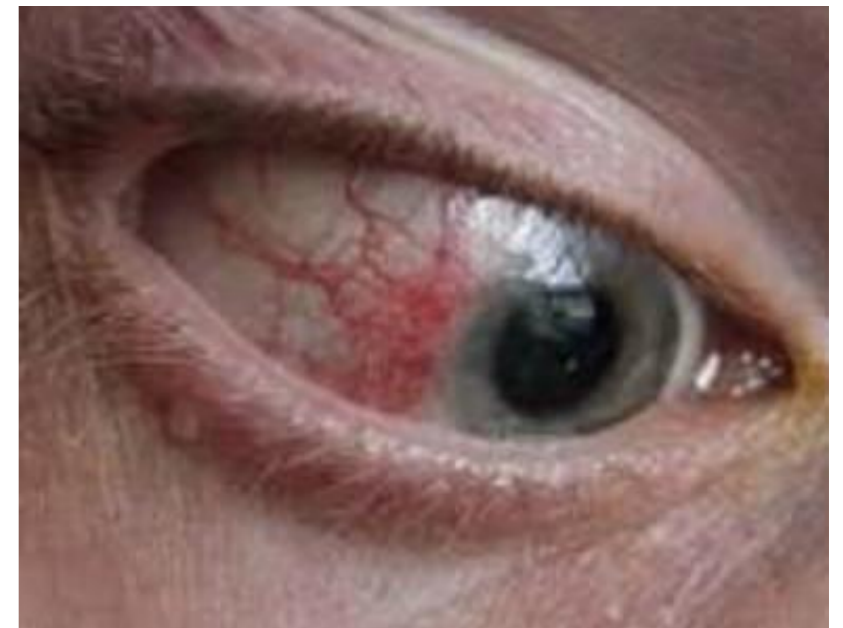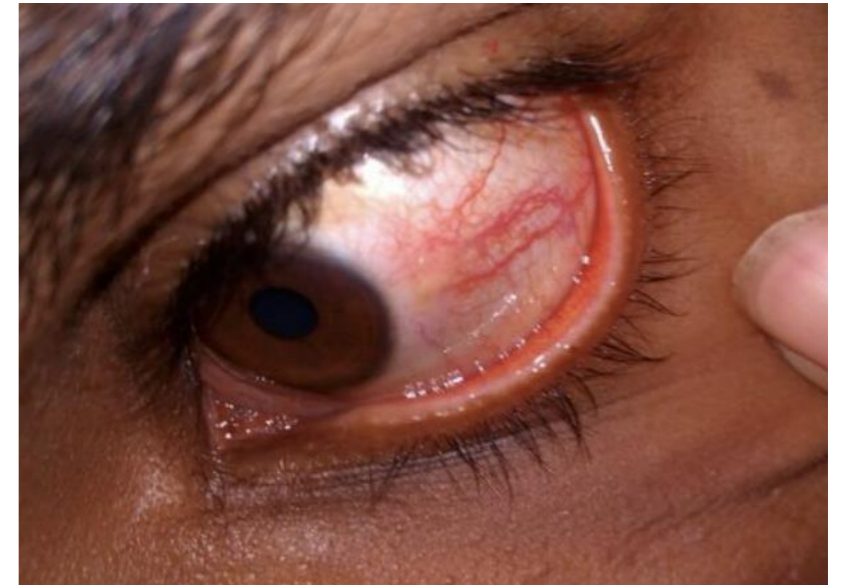Treatment

- Exclude bleeding tendency
- Check BP
- Allow to clear



Episcleritis

- Usually one sector of redness
- Usually idiopathic
 - ? connective tissue disease
- Painful, tender
- Dilated vessels over white sclera



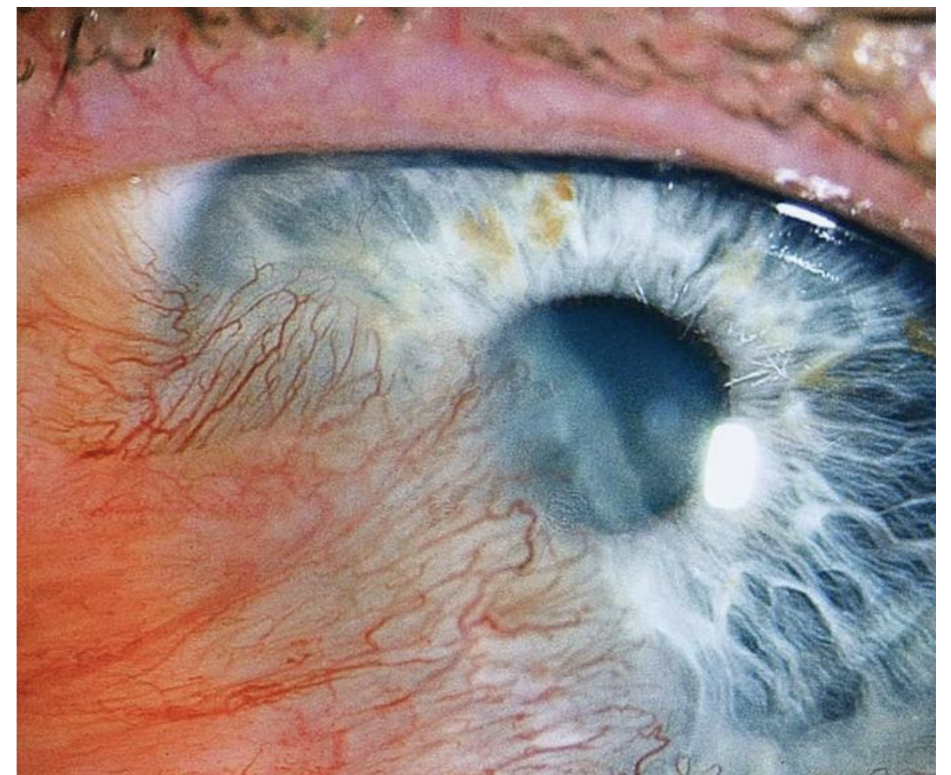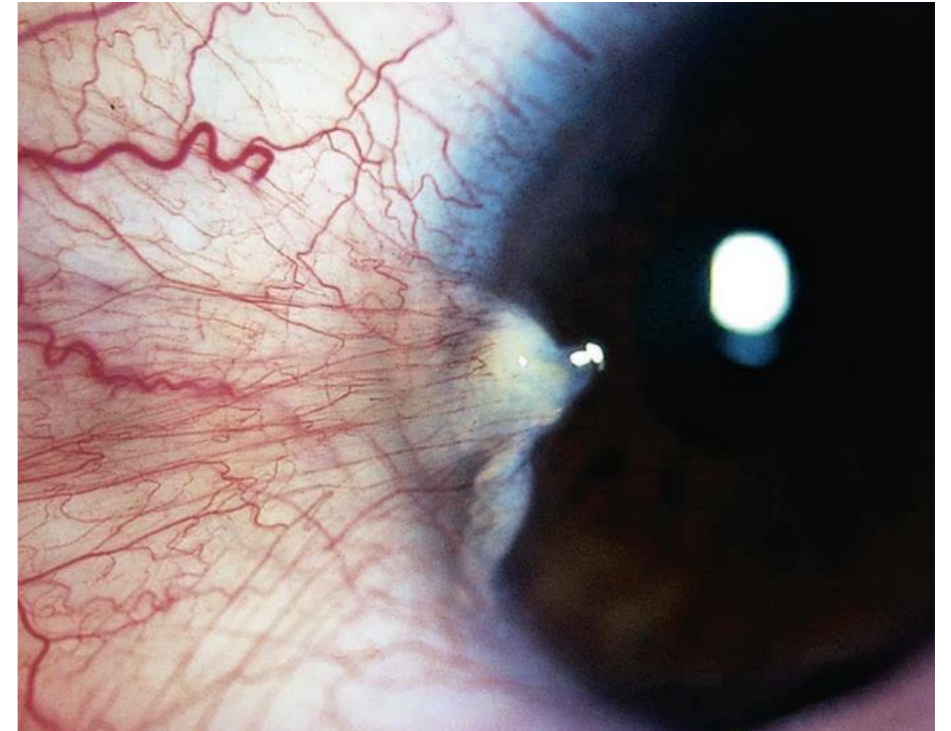
-

Pterygium

- Triangular, fleshy area of redness
- Usually progressing from nasal side onto cornea
- Often residence in tropical climates

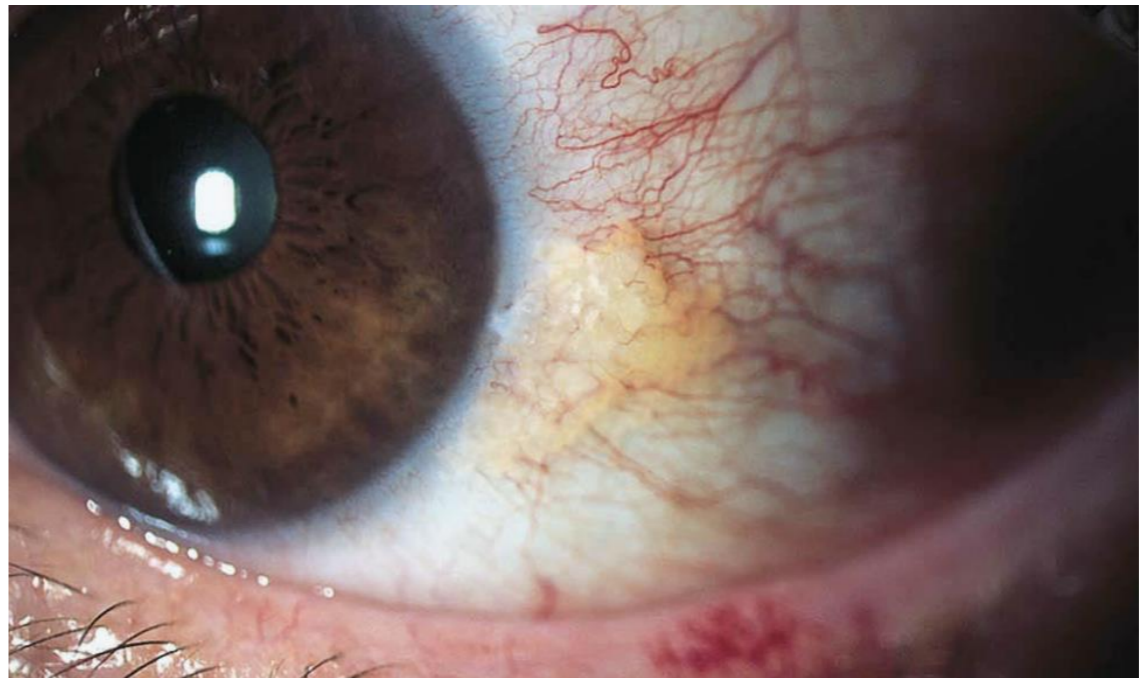
lubricants if dry

FML drops tds 1/52 if inflamed

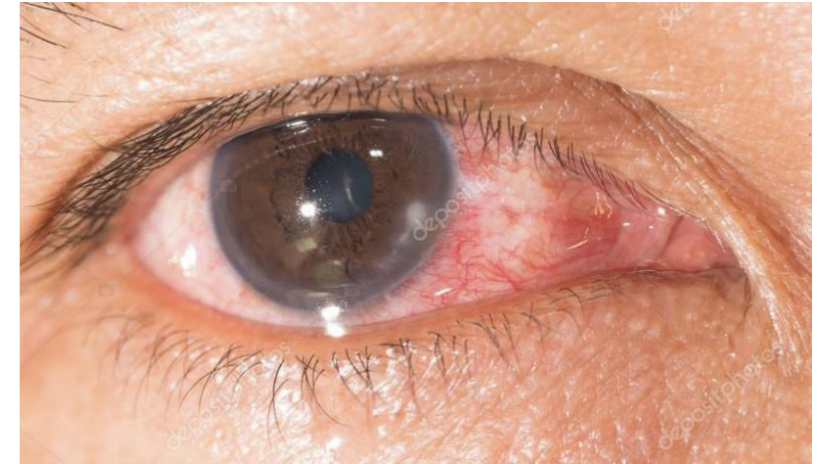


Pingueculum

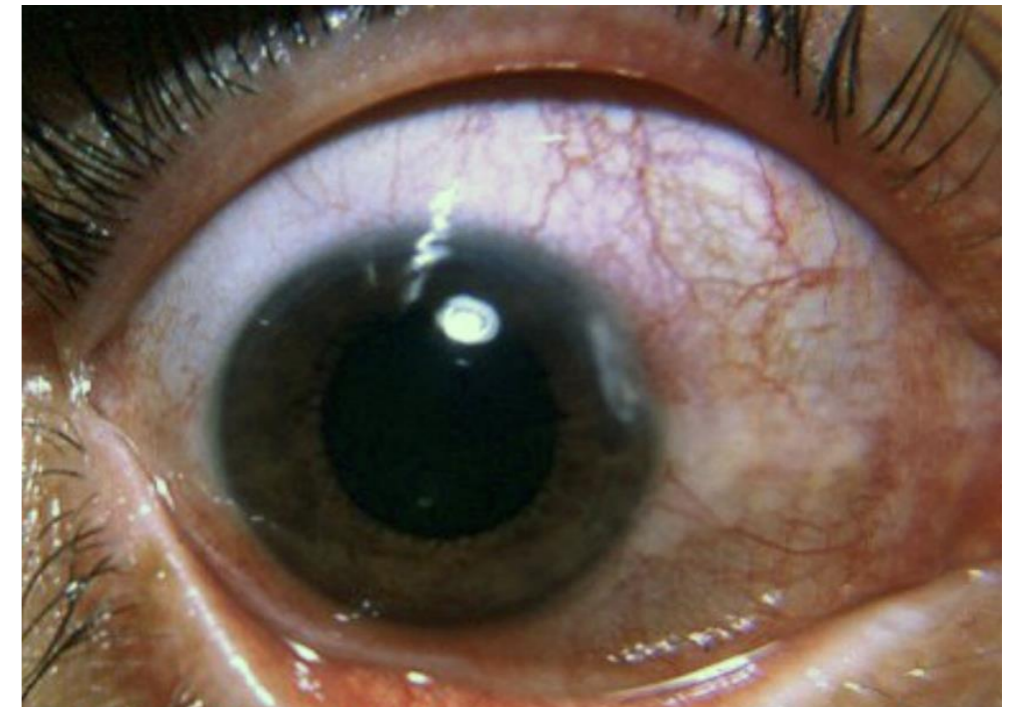- Area of yellowish lipid with vessels
- Not reaching cornea
- Sometimes elevated



Marginal keratitis

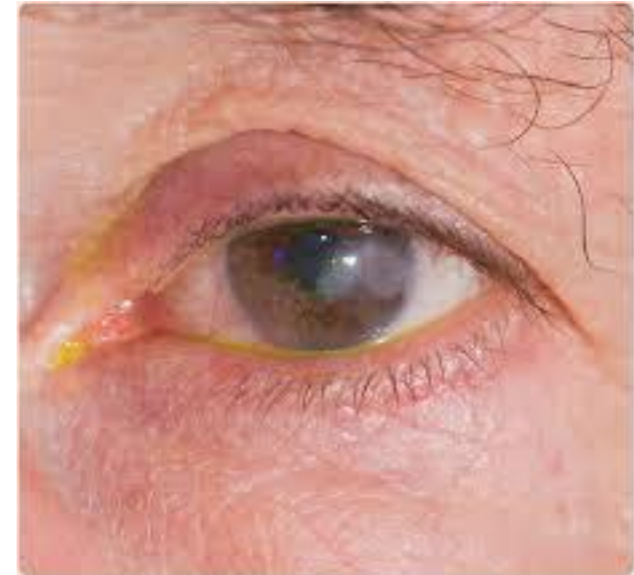

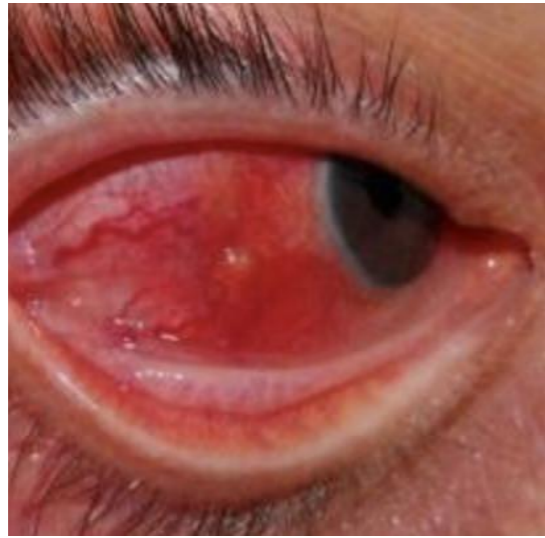
- Redness in area where lid crosses cornea (10 or 2 o'clock, 5 to 7 o'clock)
- Peripheral corneal opacity may be visible
- Treatment - early referral



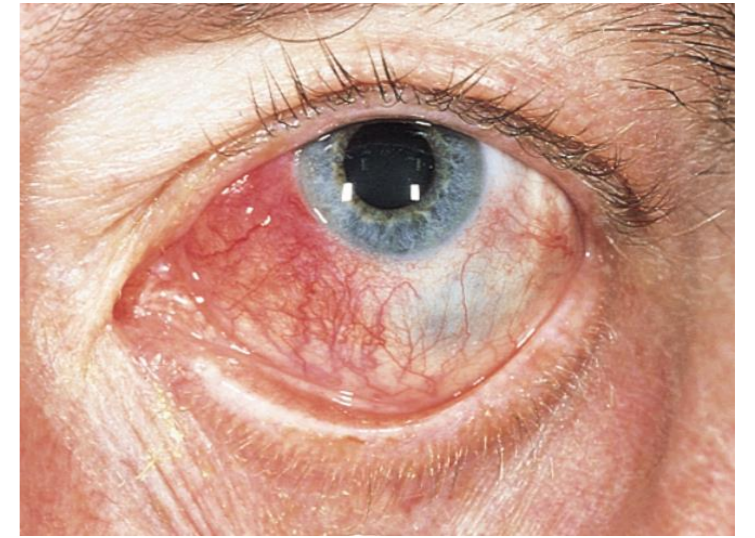
Contact Lens Related Keratitis

- Visual acuity - normal or reduced
- Pain - painful or painless
- Photophobia - yes
- Unilateral or bilateral - unilateral

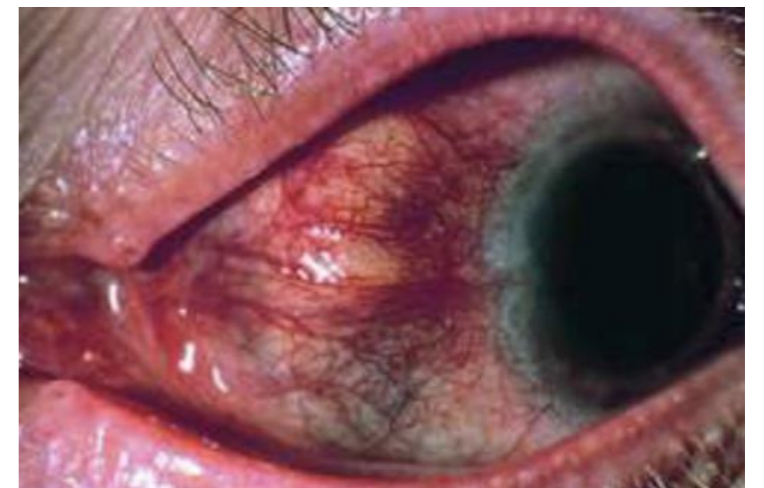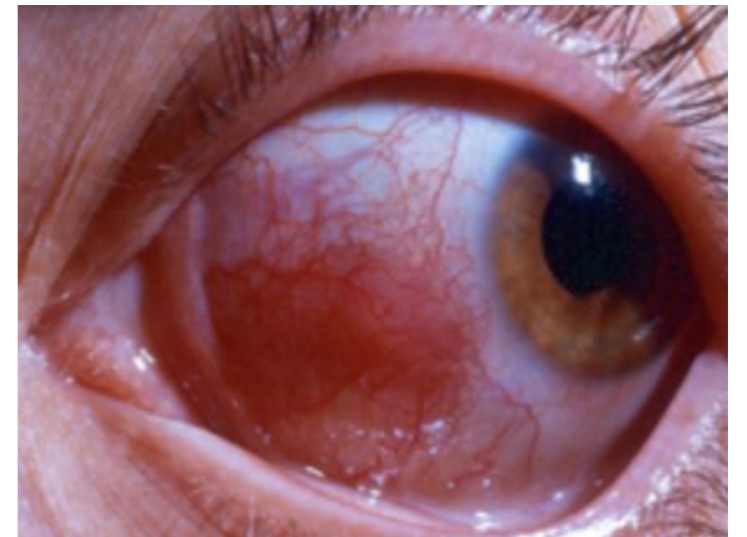




Scleritis

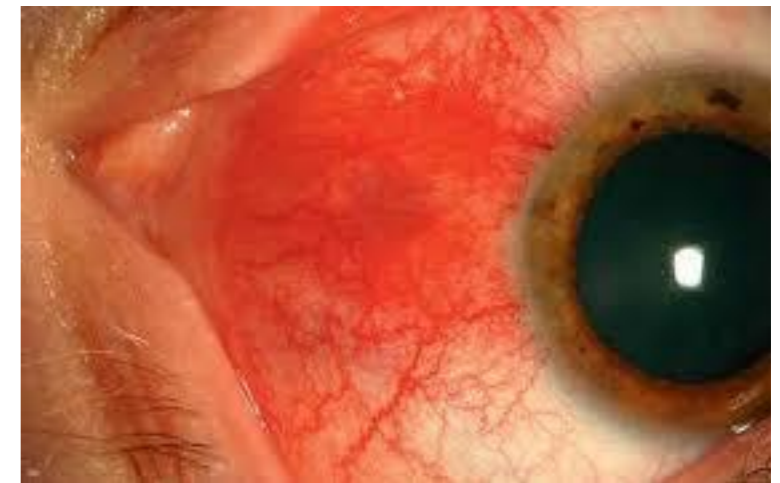

- Redness localised
- But deep scleral layer is pink
- Sometimes scleral necrosis
- Often history RhA, ANCA, ANF +ve
- Treatment - urgent referral



Scleritis

- Visual acuity - normal or reduced
- Pain - painful - cannot sleep
- Photophobia - occasional
- Unilateral or bilateral - unilateral

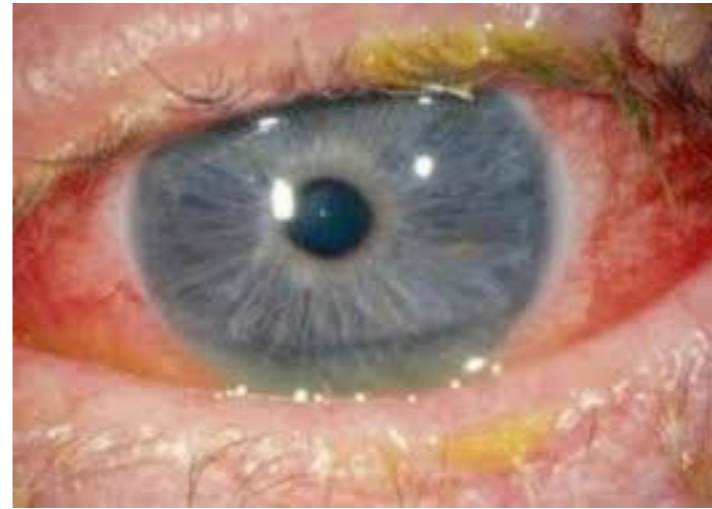

Clinical

Episcleritis	Scleritis
<ul style="list-style-type: none">• Abrupt - Days to weeks• Redness without irritation• Mild ocular discomfort - Burning, FB sensation, irritation• Localized	<ul style="list-style-type: none">• Insidious - over several days• <i>Pain</i>, tenderness to palpation, radiate• Worse at night+awake

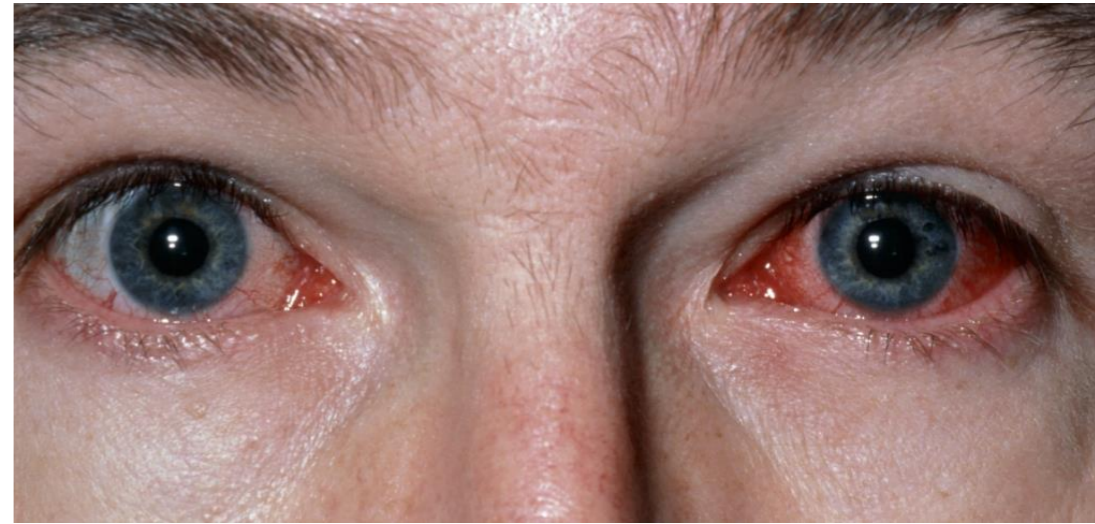Generalised Red Eye

Bacterial conjunctivitis



- Visual acuity - normal
- Pain - discomfort, no pain on eye movement
- Photophobia - none
- Unilateral or bilateral - unilateral then bilateral

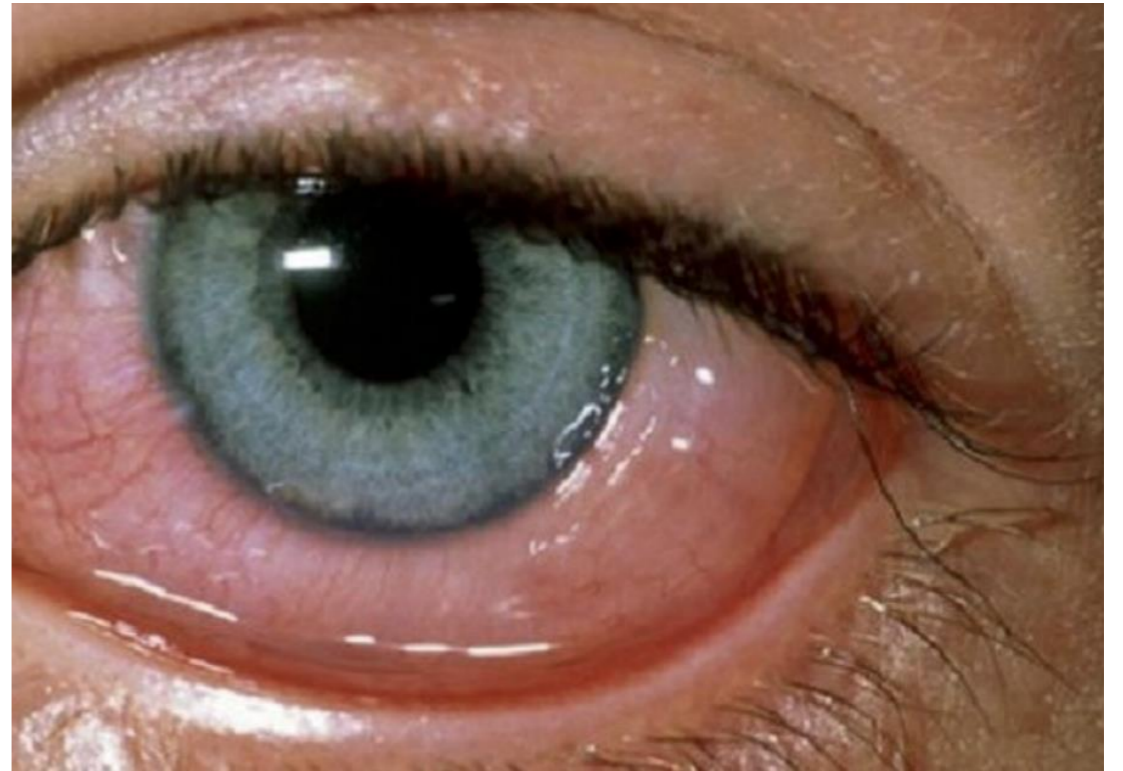Viral conjunctivitis



- Often starts unilateral and progresses to involve both
- ? Recent URTI or contact (family, school)
- Short duration of symptoms
- Generalised redness +/- lid swelling
- Lower lid conjunctiva red, “velvety”
- ? Pre-auricular lymph node palpable
- Treatment - ? topical antibiotic, hygiene (highly contagious)

Allergic conjunctivitis

- Usually bilateral
- Itchy, irritable eyes
- Watery discharge
- Coexistent allergy,

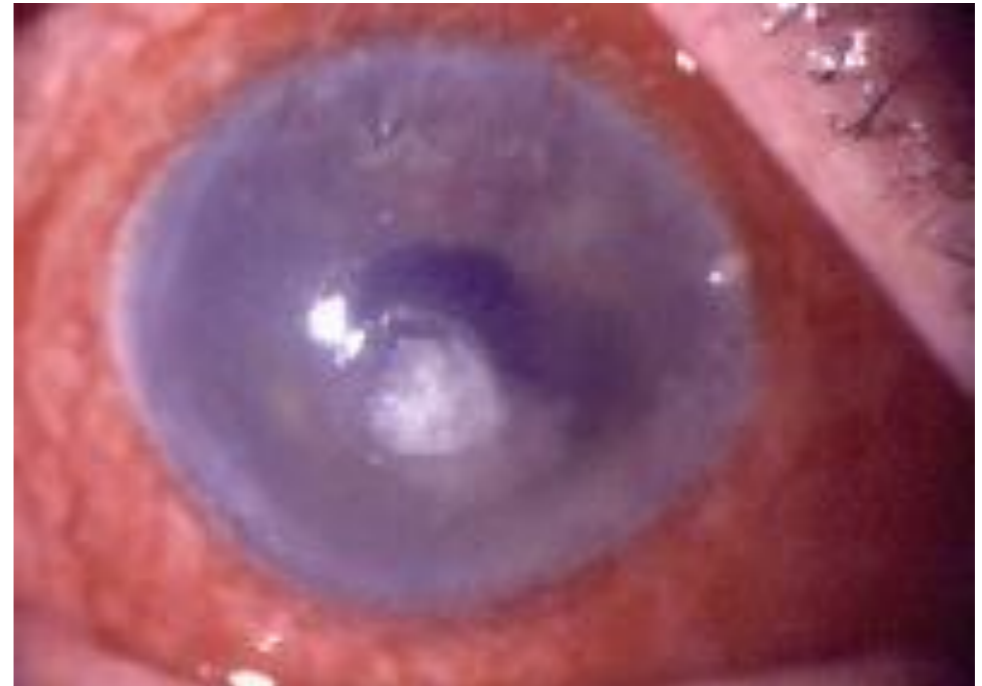


Treatment

- refer for topical steroid
- cromoglycate prophylaxis (3/52 to work)
- Opatanol tds

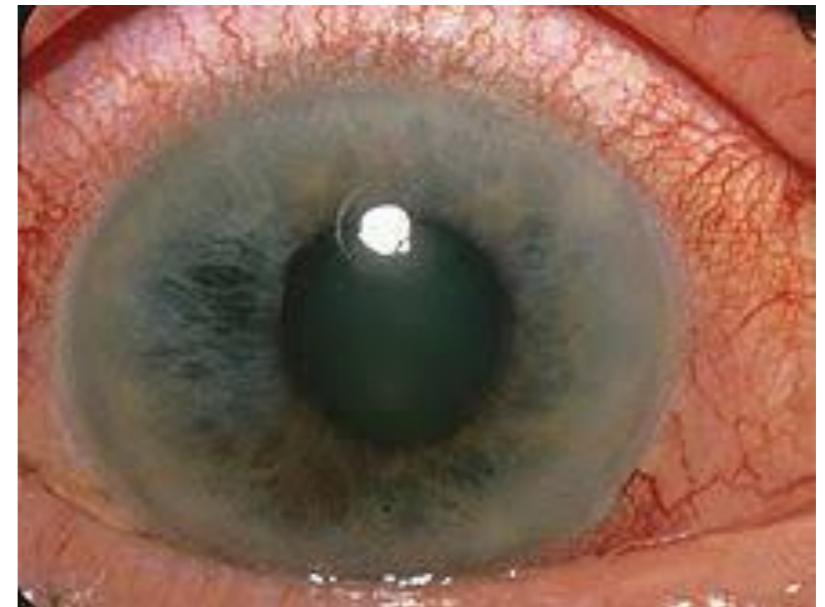
Painful Red Eye

- Acute angle-closure
- usually 60yrs +
- debilitating
- globe hard to palpation
- nausea /vomiting



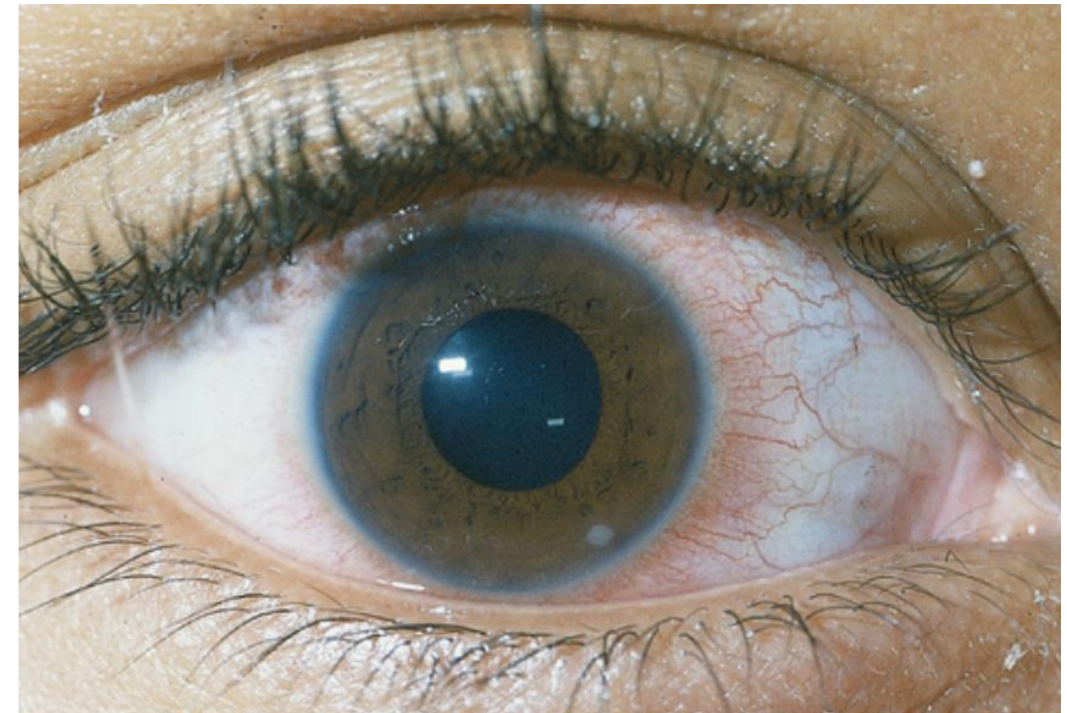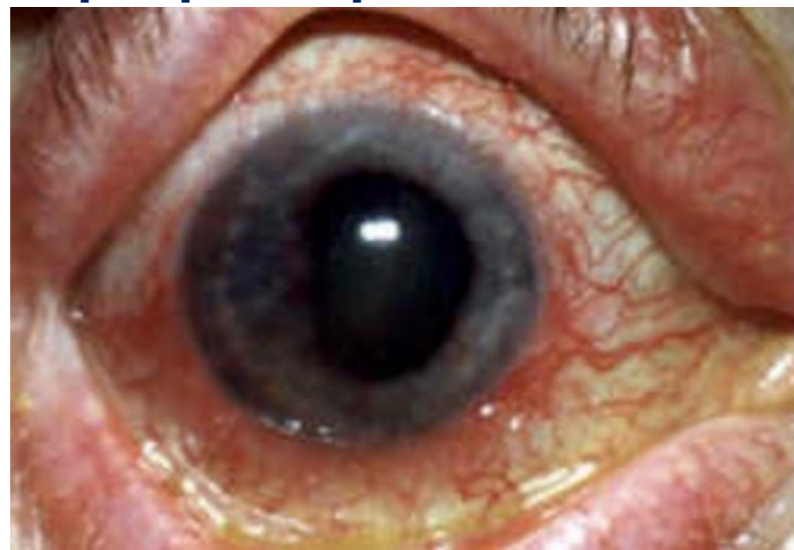
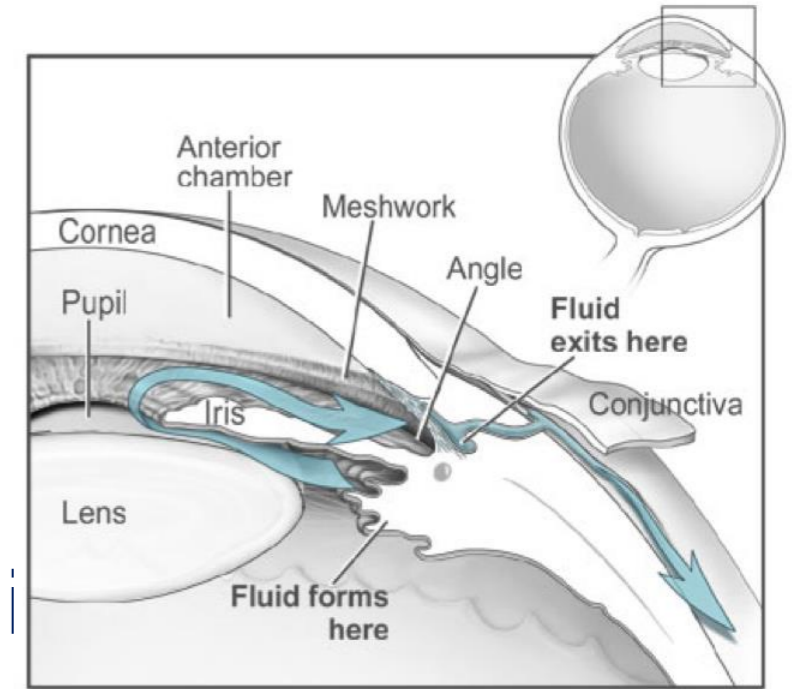
Acute glaucoma

- Visual acuity - reduced
- Pain - painful
- Photophobia - no
- Unilateral or bilateral - unilateral



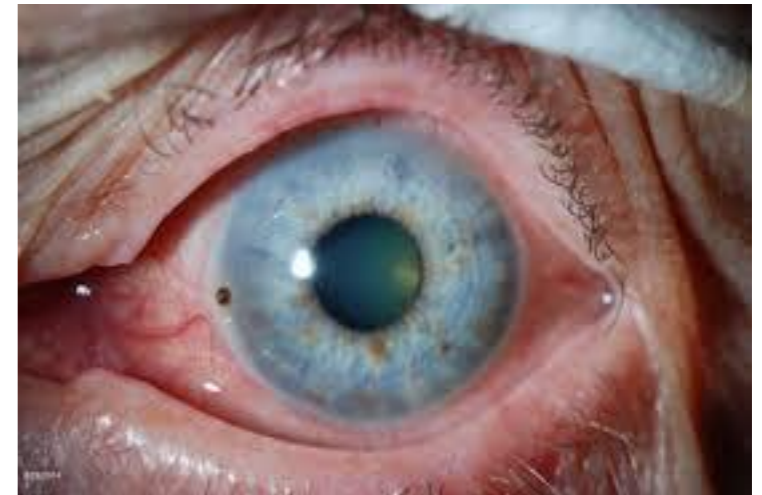
Iritis (acute anterior uveitis)

- Redness is particularly intense around the iris (PERILIMBAL injection)
- Often pain increases with light or accommodation
- ? Association with arthritis, GI disturbance, HLA-B27
- ? Irregular pupil - previous attacks

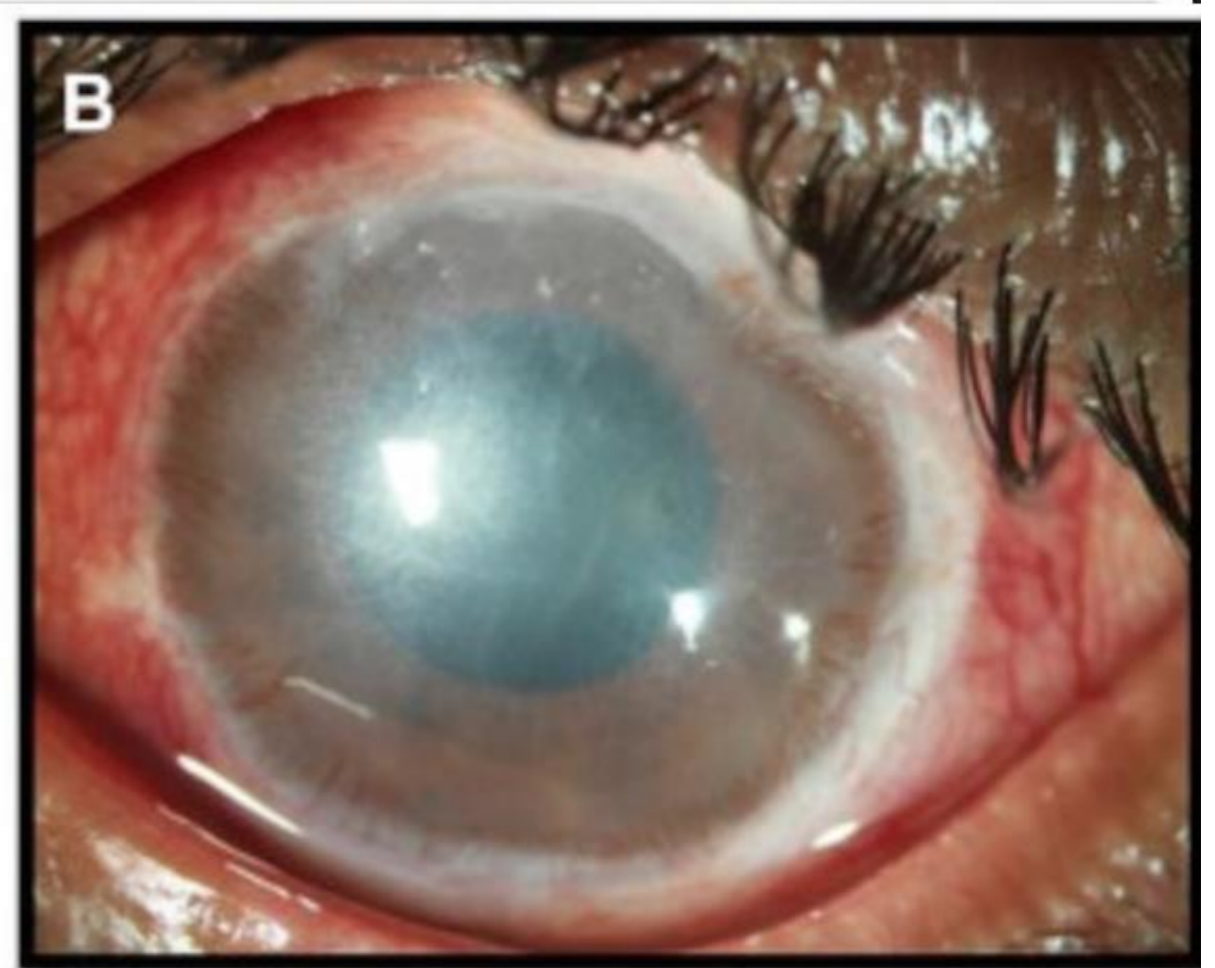
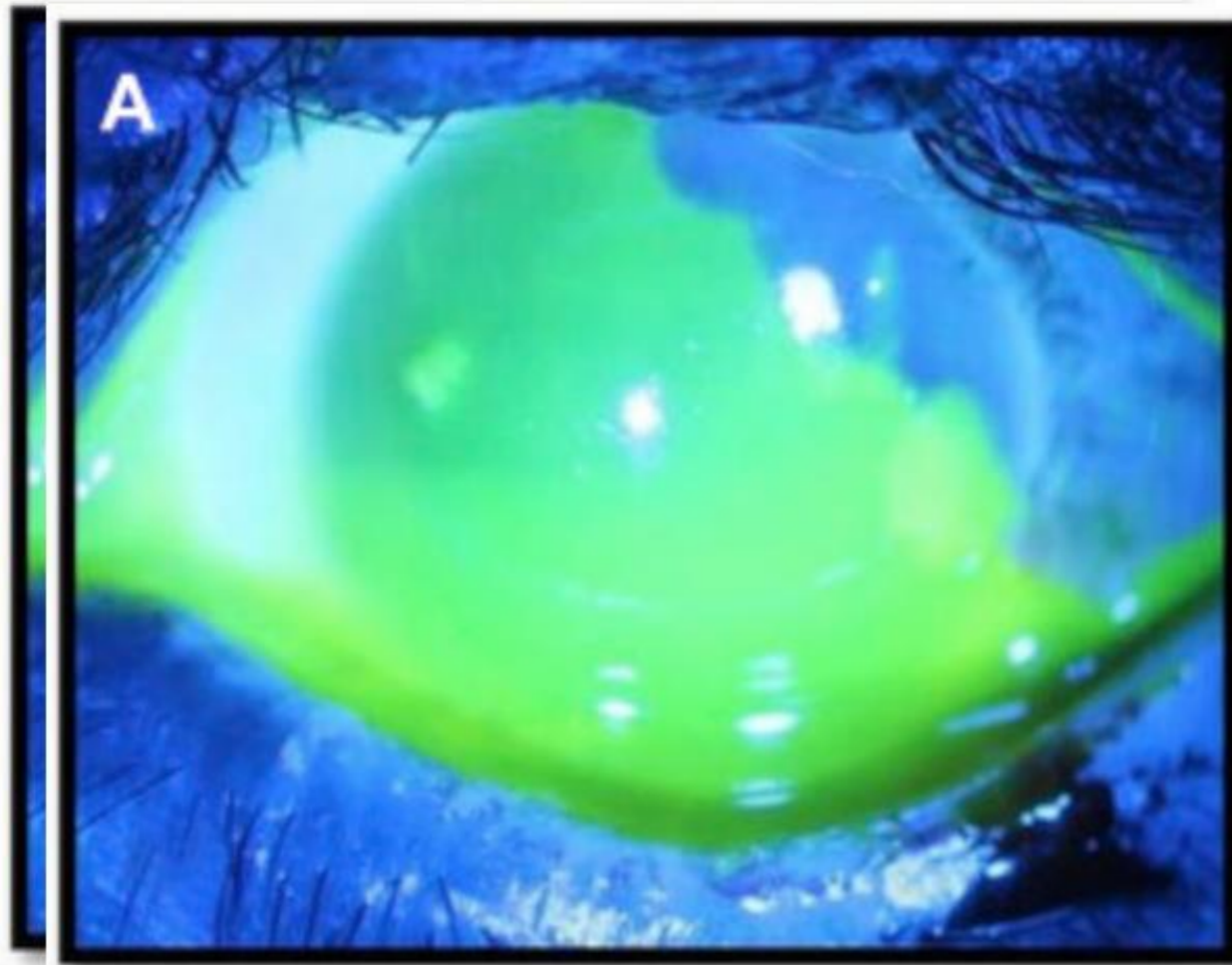


Foreign body trauma

- Visual acuity - normal or reduced
- Pain - painful
- Photophobia - occasional
- Unilateral or bilateral - unilateral

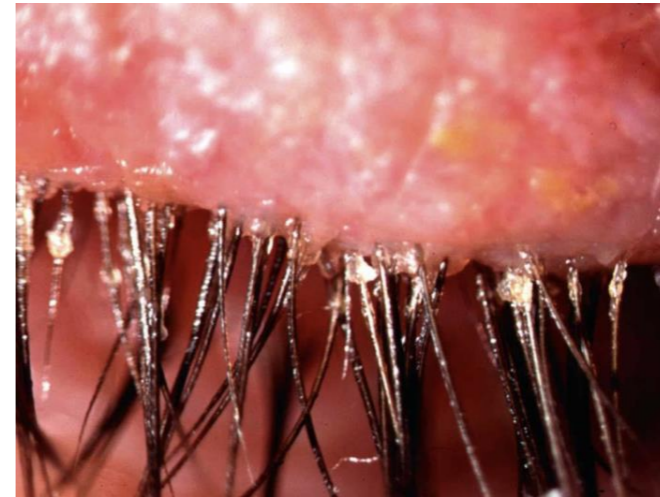

Chemical Burns

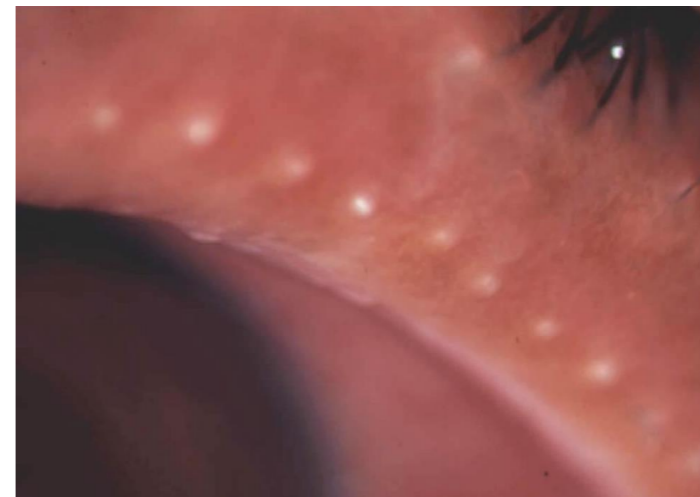


Blepharitis - 2 distinct types

- Anterior
 - Due to dry skin on lashes (collarettes)



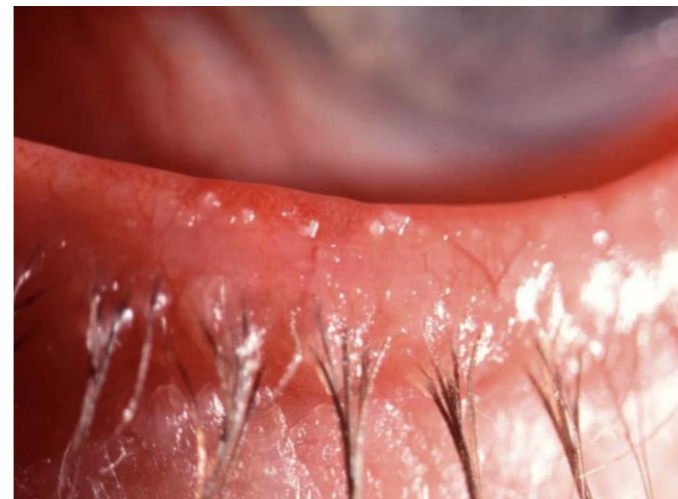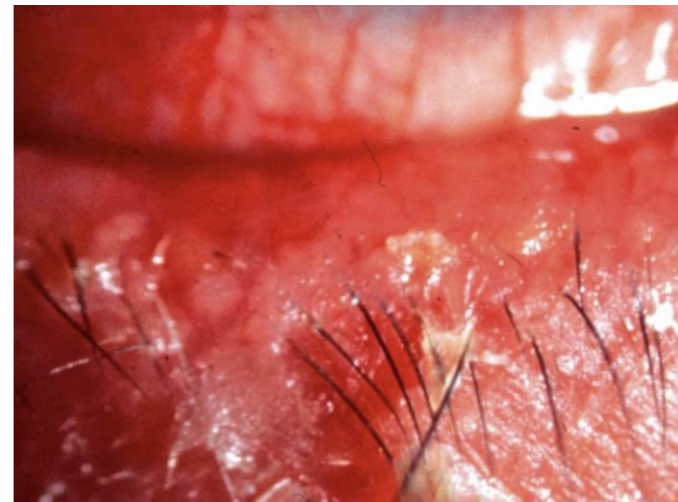
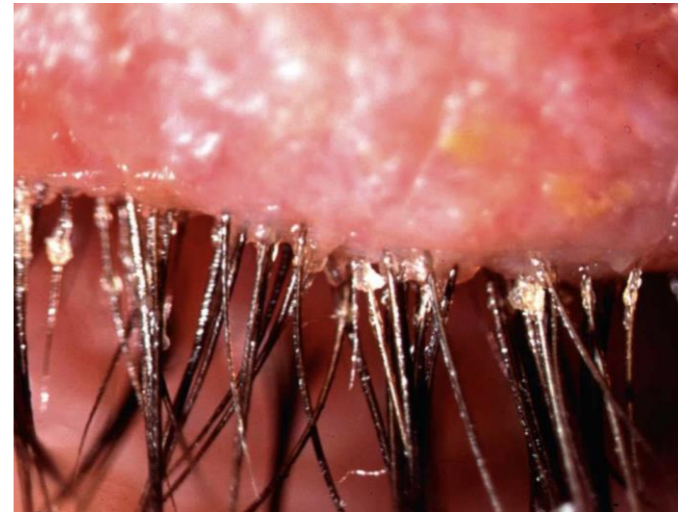
- Posterior
 - Due to plugging of meibomian glands



- May co-exist


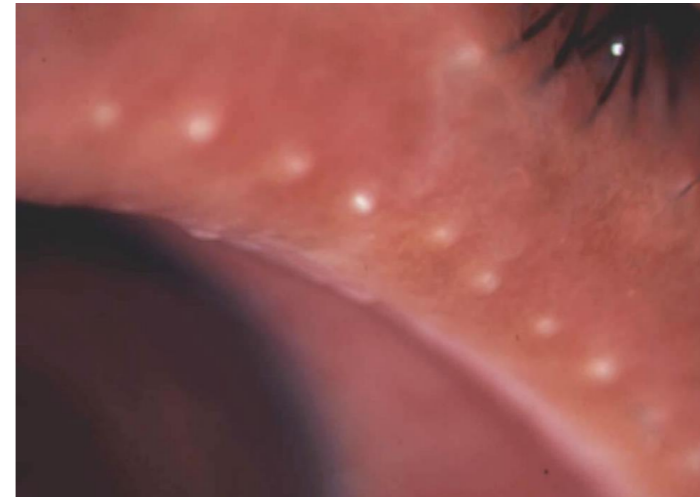
Anterior Blepharitis

- Due to dry skin on lashes (collarettes)
- Treatment
 - Daily cleaning of lids with warm water and cotton wool
 - Try to twist skin off from base of lashes



Posterior Blepharitis

- Due to plugging of Meibomian gland orifices
- Treatment
 - Hot compresses nocte to soften lipid secretions
 - EyeBag
 - If eyelid margins erythematous consider doxycycline 100mg od 1/52



Wheat Bags Value Cotton Eye Mask Heat Pack

£4.95



Rated 4.8 out of 5 based on 58 customer reviews.

Wheat Bags Value Cotton Eye Mask Heat Pack from WheatyBags® is a microwave eye pillow made in the UK and offers great coverage across the eye or face area.

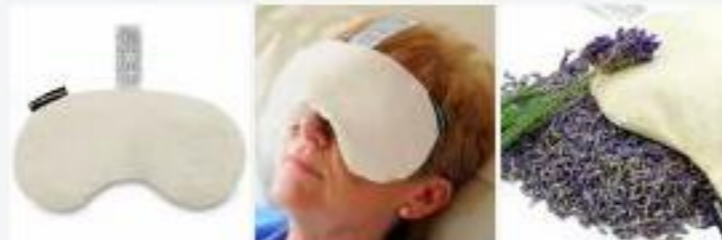- Expertly designed microwave eye wheat bag.
- Assorted colours subject to available stock.
- Natural cotton fabric.
- Heat pack for Blepharitis, MGD and dry eyes.
- Choose between wheat or linseed filling.
- Fully safety compliant with BS8433.
- UK made.
- Trusted WheatyBags® brand.

** SPECIAL OFFERS **

Click below to redeem.



Move your mouse over image or click to enlarge



[Order](#)

[Details](#)

[FAQ](#)

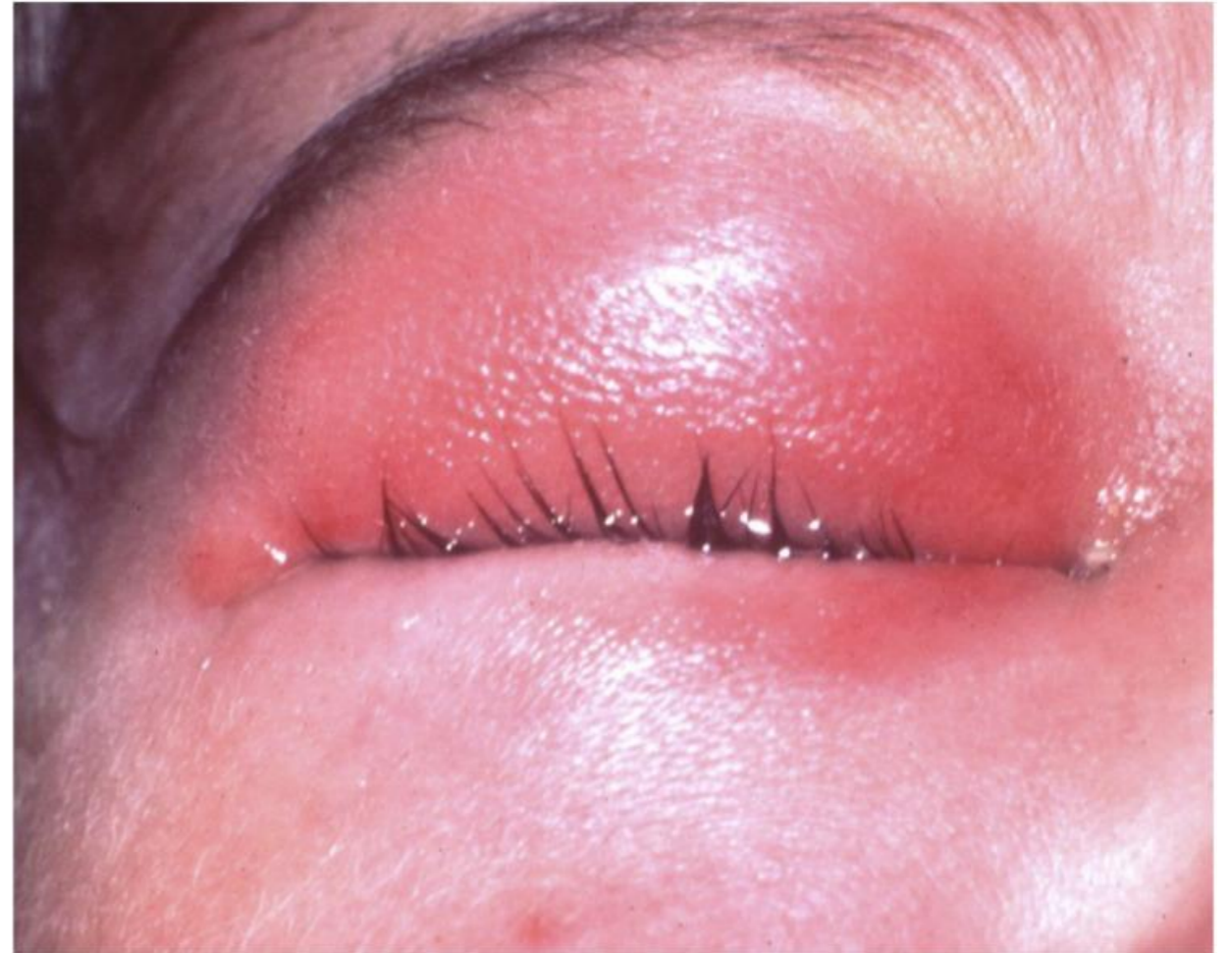[Instructions](#)

[Reviews](#)

£4.95 + delivery from £2.95

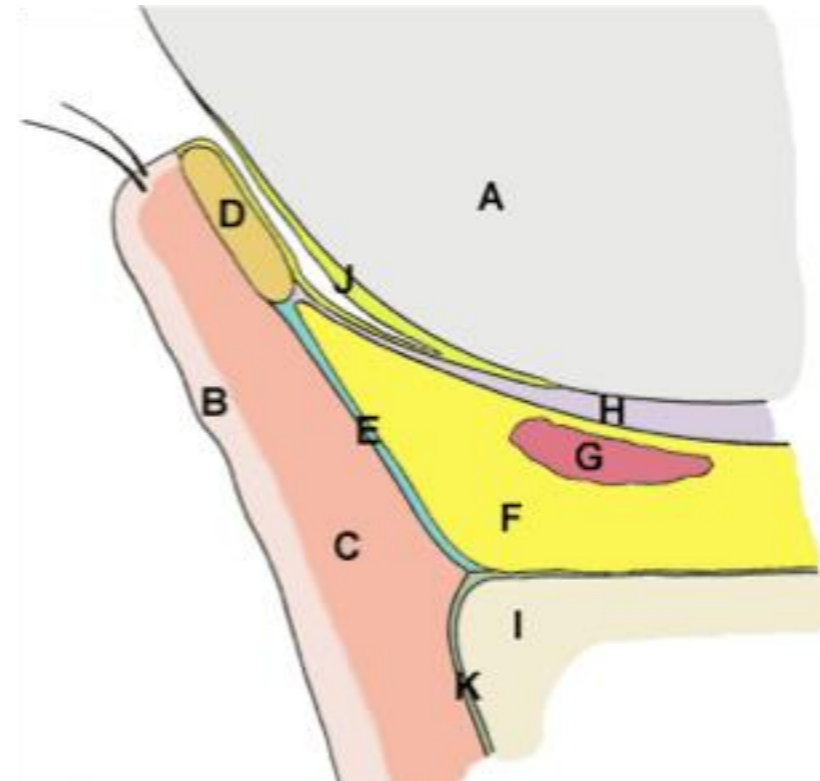
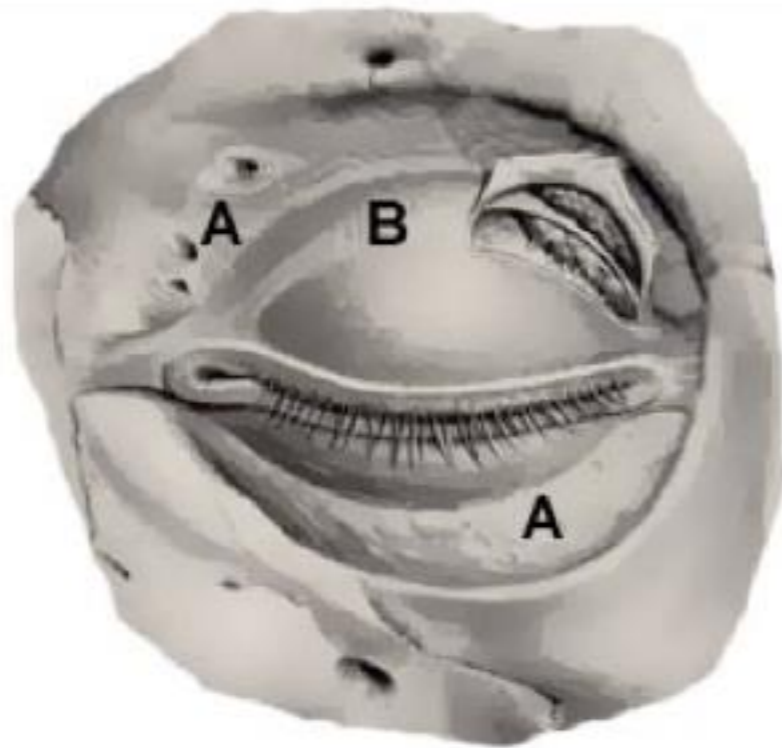
Unilateral swollen eyelids

- Possible orbital cellulitis
- Usually preseptal cellulitis due to chalazion



Orbital septum

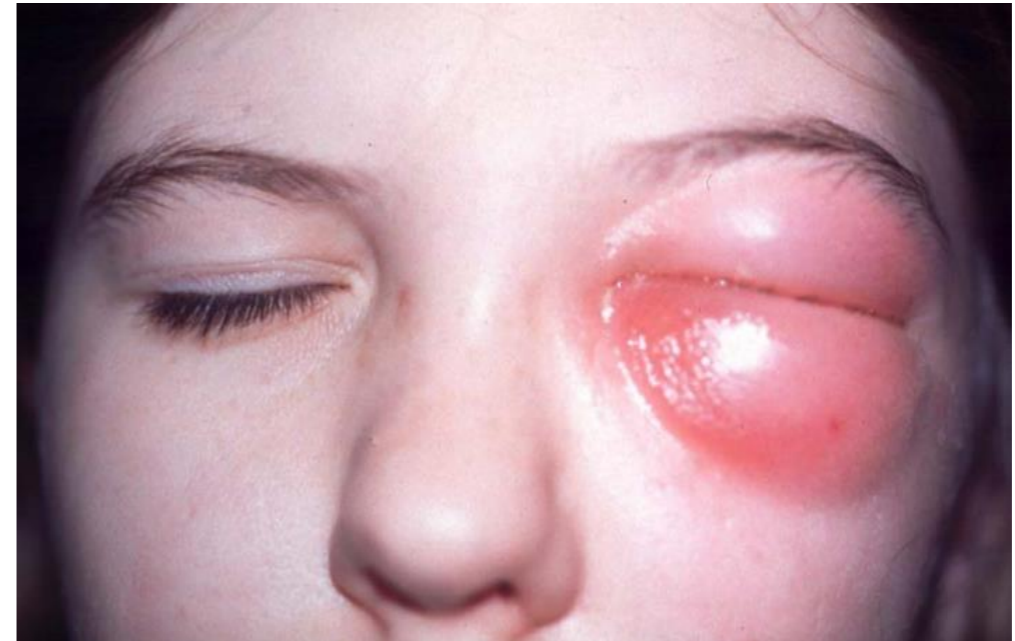- demarcates the orbit from the eyelids



- the orbit is involved, the function of the orbital structures will be affected
- pupil, extraocular movement, (conjunctiva)

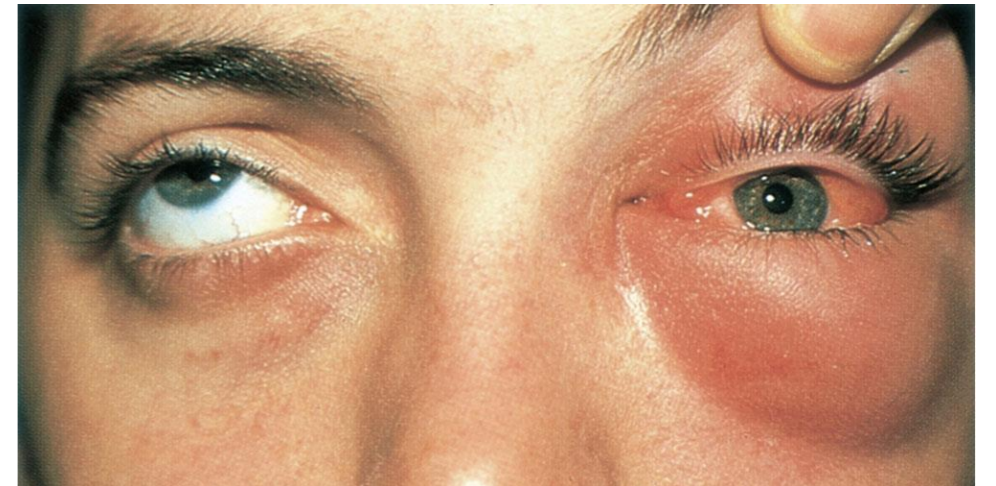Orbital Cellulitis

- Acute onset lid swelling
- Malaise
- Fever
- Infection involves tissues within orbit
- Orbital signs
- **Emergency**



Orbital cellulitis

- Visual acuity - normal or reduced
- Pain - painful
- Photophobia - no
- Unilateral or bilateral - unilateral



Preseptal vs Orbital Cellulitis

PRESEPTAL

Infection confined to eyelids

- White eye
- Normal eye movements
- Normal vision
- Responds to antibiotics
- Observe adults
- Refer children - may progress rapidly

ORBITAL

Infection involves orbital tissues

- Red eye
- Restricted mobility
- Vision reduced
- Abnormal pupil reaction
- Fever, malaise
- Observe adults
- Requires urgent admission

Questions?

Refer any person with a red eye who wears contact lenses urgently to ophthalmology to exclude corneal ulcer.

- *Refer any person with a high-velocity injury immediately to the emergency eye service. Imaging of the orbit is needed to check for intraocular foreign body.*
- *For people with chemical eye injury immediately irrigate the eye with water or 0.9% saline, and arrange urgent transfer for ophthalmology assessment.*
- *Refer any serious, and potentially sight-threatening case*