

Genital Conditions in Children and Young People

Dr Katie Malbon

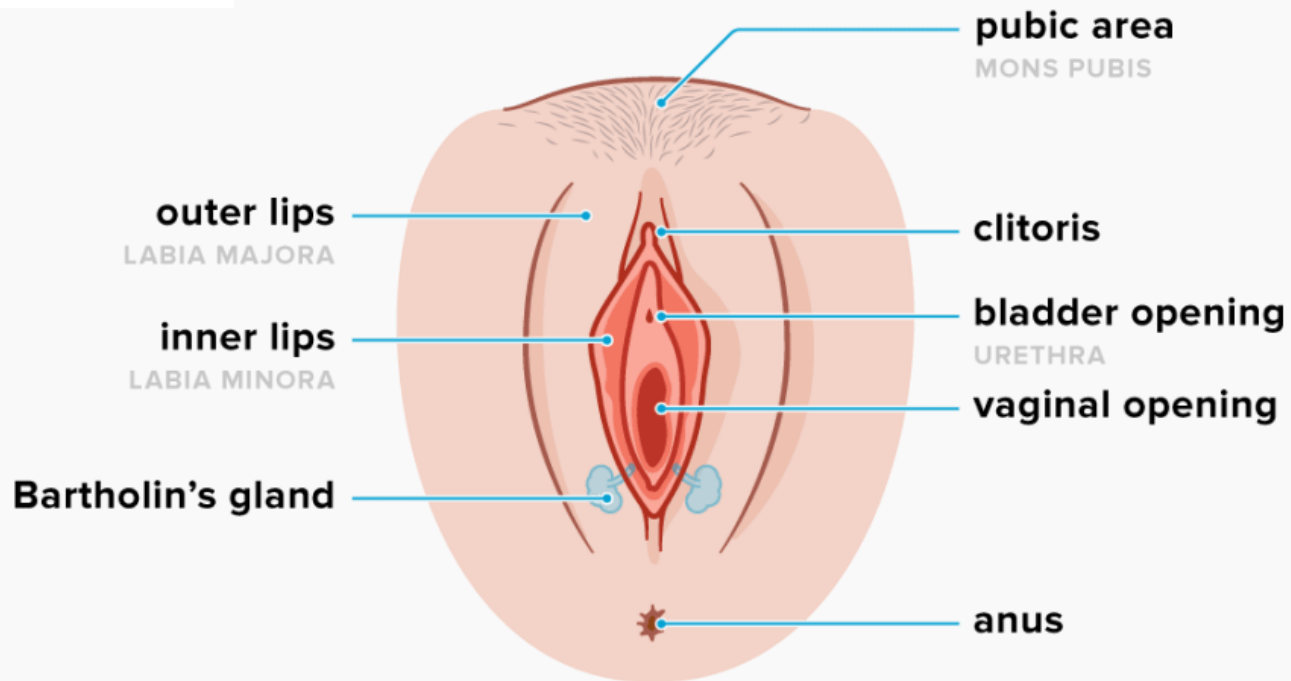
Consultant Paediatrician

Imperial College Healthcare NHS Trust

May 13th 2021

Learning Objectives

- To know the important questions to ask when a child or young person presents with a genital concern
- To recognise common genital conditions in children and young people
- To understand the management of common genital conditions in children and young people



The Anatomy

Case 1

10 years old child presents with severe vaginal pain at night not responding to painkiller. Describe as sharp and burning type from the vulva into the vagina.

The patient does not have her period but shows early signs of puberty. There is no discharge.

Over the past 3 years she had occasional episode but pain was much milder and shorter. Currently pain is preventing the child to sleep and so painful that mum has provided recording of the child crying and screaming in pain.

The child has also noticed that she cannot wear jeans anymore and feels uncomfortable with legging during PE lesson.

There is no safeguarding concern.

The examination swab and pelvic scan are within the normal.

What more do we want to know?

What more do we want to know?

When the pain occurs (day/night/anytime)

Anything make it worse

Anything make it better

Associated symptoms – itch, discharge, bleeding

Washing/toileting regimen

General skin condition

Allergies

Case 1

Mum changed laundry detergent, symptoms have resolved

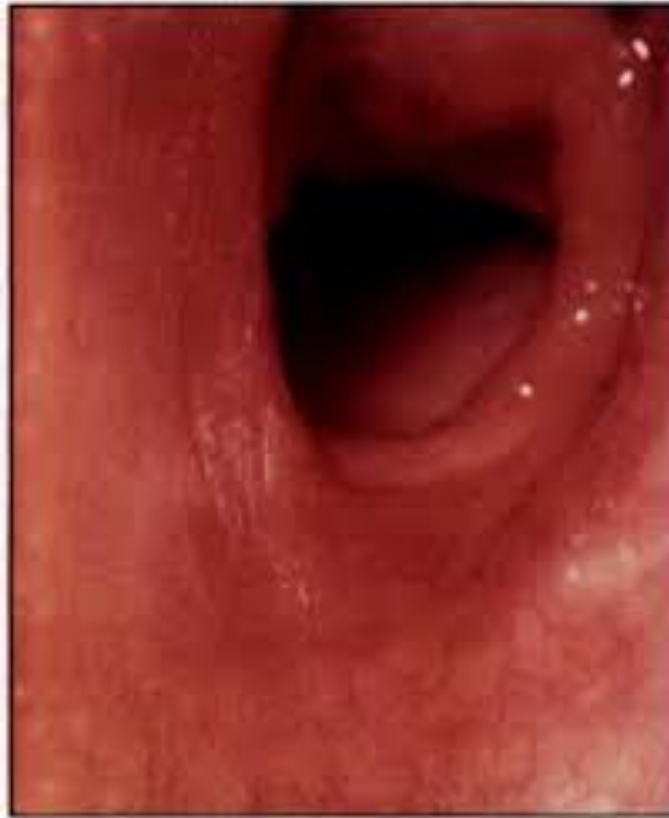Long history of sensitive skin/eczema

Washes genital area 3-4 times a day

Uses sensitive skin wash

Uses Sudocrem – not sure if it helps

Case 1



Vulvovaginitis

- Most commonly from over washing causing drying of the skin
- More likely if has eczema/atopy
- Common in young children due to:

Inadequate hygiene

Lack of protective hair & labial fat pads

Lack of oestrogen

Symptoms

Pain

Itching

Discomfort

Discharge

Bleeding

Management

General advice

- Reduce washing
- Shower rather than bath
- No bubblebaths/soaps
- Cotton loose clothing

Rx

Dermol 500 as a soap substitute

Cetraben emollient apply 2-3 times daily

Complications

Bacterial infection

- Presents with discharge +/- bleeding
- Commonly streptococcus

Rx: Clindamycin cream or po Amoxicillin

HSV infection

- Presents with multiple painful vesicles

Rx: Po Acyclovir and lidocaine gel

No response to treatment?

Swab again

- Untreated infection

Biopsy

- Lichen Simplex

Rx: Topical steroids and simple vulvovaginitis treatment

Learning points!

VERY RARELY CANDIDA!

Low Vaginal Swab
Only treat once result available

Always give general advice re genital skin care, use of Dermol 500 and emollient

Case 2

I would be most grateful if you could see this 6 year old girl. Clinically, she has a sclerotic patch on her left lower anterior neck which resembles extra-genital lichen sclerosus et atrophicus.

She also has evidence of genital lichen sclerosus et atrophicus. I would be most grateful if you could see with a view to genital assessment, but in particular, undertaking a genital punch biopsy for histology. Mum is aware that you will be contacting her with an appointment, and I have arranged to see her again with these results.

In the meantime, I have recommended she uses some Eumovate ointment to the affected areas.

What more do we want to know?

What more do we want to know?

Genital discomfort

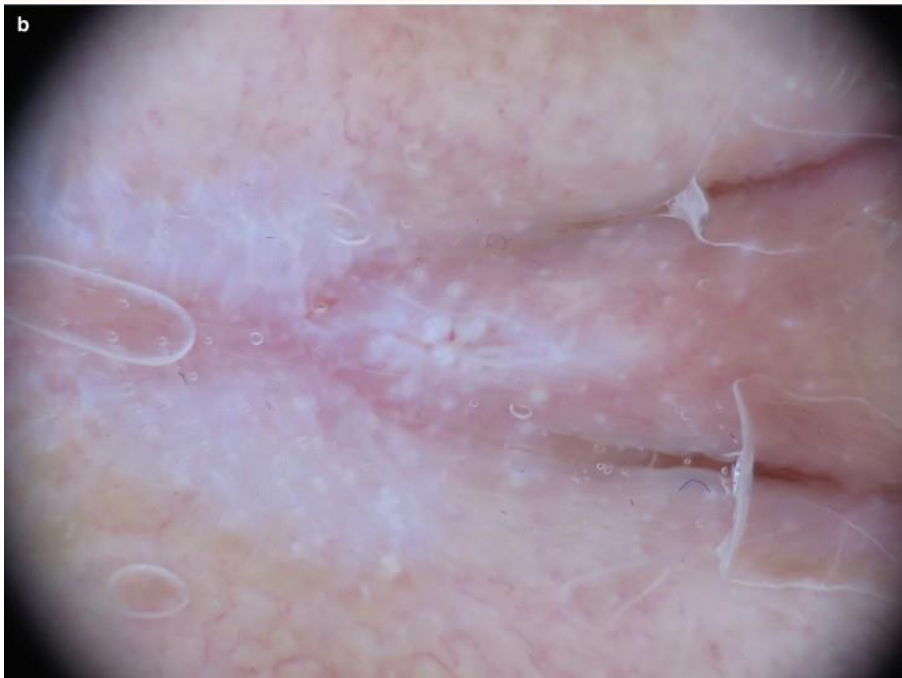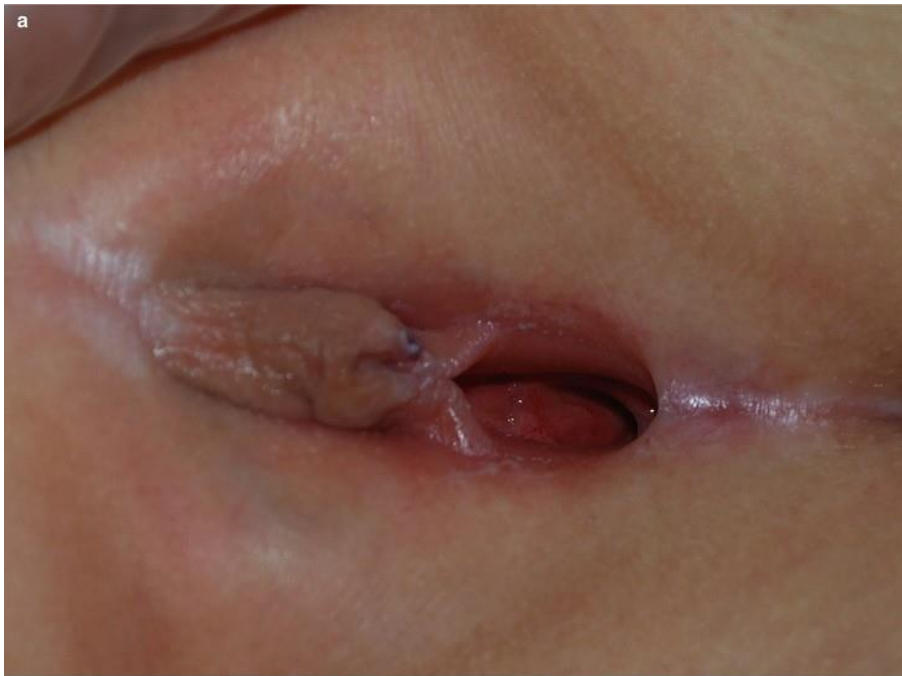Genital itching

Vaginal discharge

Vaginal bleeding

Lesions elsewhere

Family history



Lichen Sclerosis - Treatment

Cetraben Emollient

Dermol 500 as soap substitute

Topical Steroids for flares (Hydrocortisone or Eumovate)

Learning points!

BIOPSY IS ESSENTIAL

Can show malignant change – annual review

Always give general advice re genital skin care, use of Dermol 500 and emollient

Case 3

This 15 yo lady seems to have developed 2 month history of an extra tag like lesion on posterior entrance of her vaginal area/ perinium. It is very tender/ sensitive and is causing her a lot of discomfort.

Please would you kindly review her.

What more do we want to know?

What more do we want to know?

How she noticed it

What sort of discomfort

Genital itch

Vaginal discharge

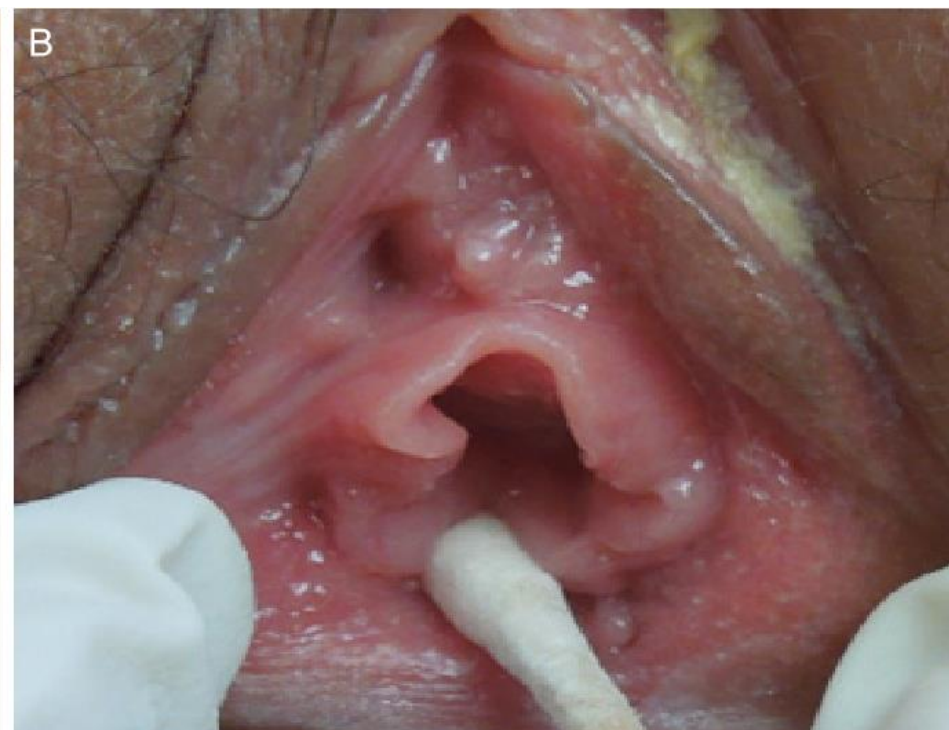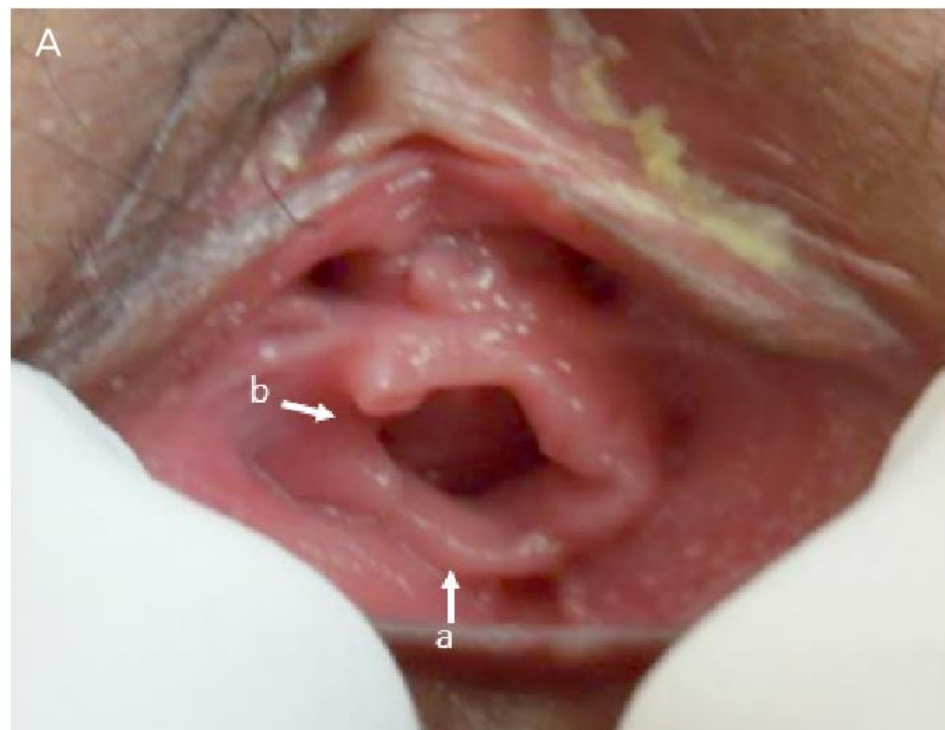Menarche

Periods

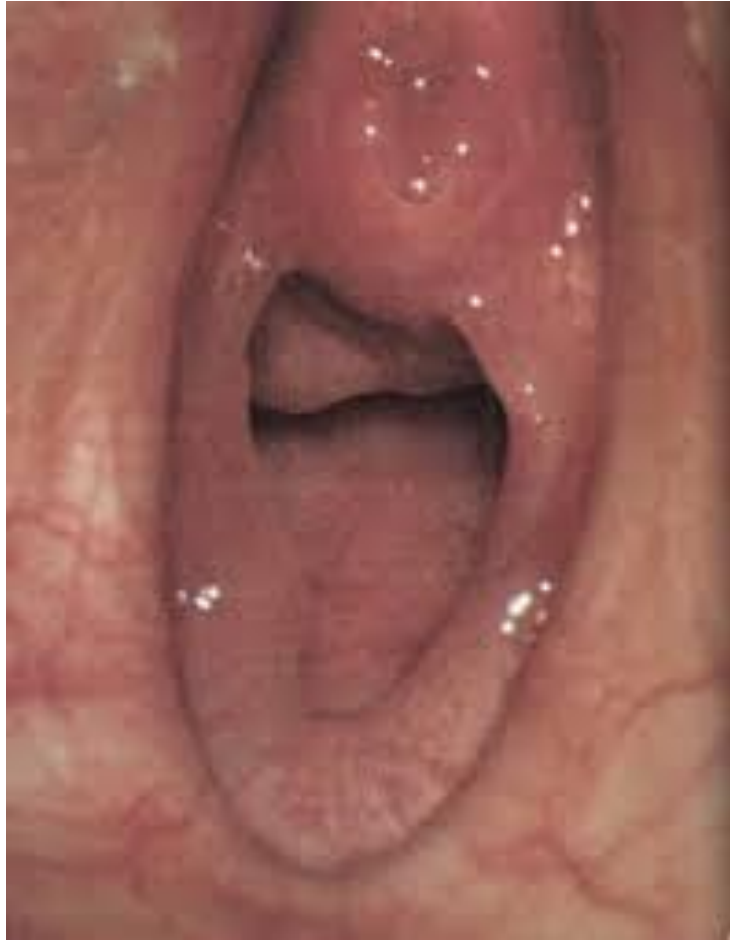Tampon use

Social history

Sexual activity



Hymenal Caruncle



Chronic Sexual Abuse

Hymenal Caruncle - Treatment

If interfering with daily living –
Surgical intervention

Findings: posterior prominent hymenal caruncles
normal anatomy

Sterile Preparation: With chlorhexidine.

Anaesthesia: General.

Operation Note: Operation Note

- hymenal caruncles excised with monopolar diathermy, no bleeding

Learning points!

SOCIAL & SEXUAL HISTORY VITAL

Surgery is simple and can make a difference

Always give general advice re genital skin care, use of Dermol 500 and emollient

Case 4

Examination today with Dad with consent

well 2 yo female child

urethra visible anteriorly

however ?imperforate hymen / agenesis of lower vagina
will refer paed - SMH

Dear Paediatrician, please see re above

What more do we want to know?

What more do we want to know?

When first noticed – from birth or new

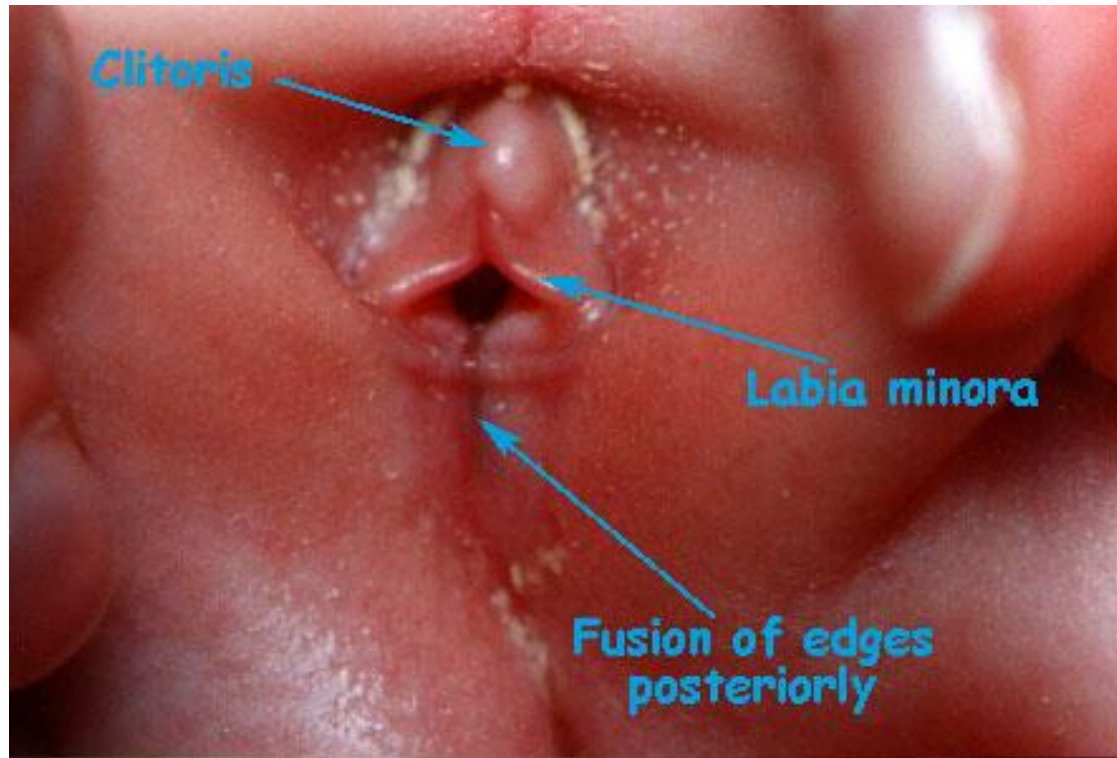
Genital discomfort

Genital itching

Vaginal discharge

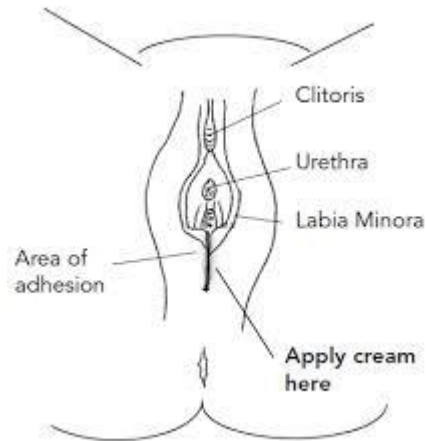Vaginal bleeding

Urine stream



Labial adhesion

Labial adhesion- Treatment



- Emollient or oestrogen cream
- Dermol 500

Surgical intervention if:

- Concerned about anatomy behind fusion
- Post pubertal

Learning points!

KNOW THE ANATOMY

Reassurance is key

Always give general advice re genital skin care, use of Dermol 500 and emollient

Case 5

Dear Paediatrician. Please see this 15yo girl.

When taking out tampons noticed a piece of skin over the vagina which bothers her. wants this checked-no other symptoms. no vaginal pain/discomfort.

What more do we want to know?

Genital discomfort

Genital itching

Vaginal discharge

Vaginal bleeding

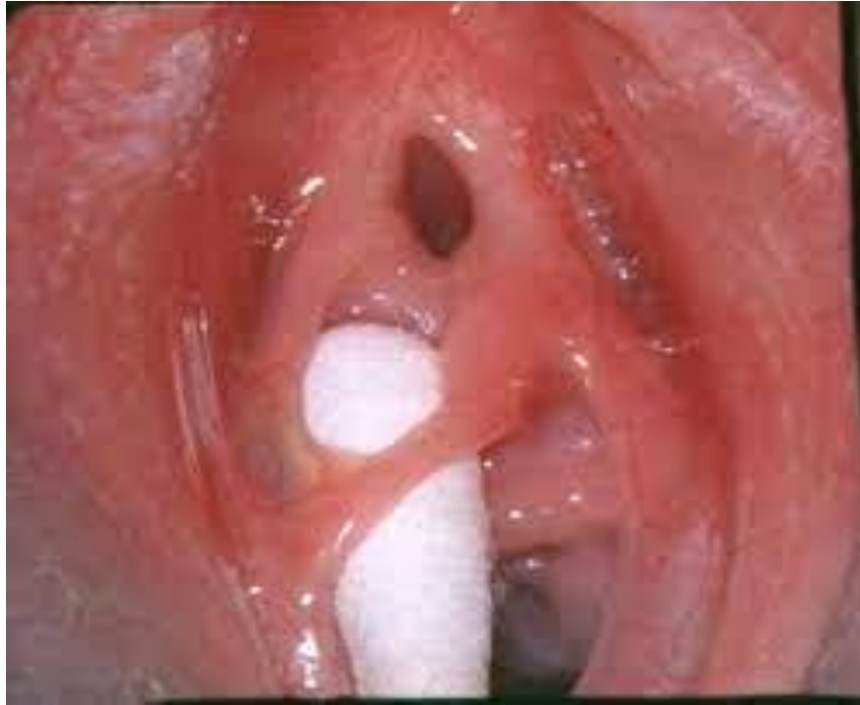Social history

Sports etc

Menstrual history

Pads or tampons

Sexual history



Hymenal Band

Hymenal Band - Treatment

Surgical excision

Cetraben Emollient

Dermol 500 as a soap substitute

Learning points!

KNOW THE ANATOMY

Importance of social history

Always give general advice re genital skin care, use of Dermol 500 and emollient